

CLINICAL TOXICOLOGY, 16(4), pp. 487-497 (1980)

## Poisoning with 4-Aminopyridine: Report of Three Cases

DANIEL A. SPYKER, PhD, MD  
Department of Internal Medicine

CARL LYNCH, MD, PhD  
Department of Anesthesiology

JEFFERY SHABANOWITZ, BS  
Department of Chemistry

JUDY A. SINN, BS  
Department of Pathology  
University of Virginia  
Charlottesville, Virginia 22908

### INTRODUCTION

4-Aminopyridine was developed by Phillips Petroleum Co. and marketed in 1963 as an avicide under the name Avitrol. The manufacturer considers this a bird "repellant" because only a small number of birds are acutely poisoned, become disoriented, and emit a distress cry "which touches a deep rooted instinct in other members of the flock to avoid undesirable places." However, the compound is acutely toxic to all vertebrates studied.

4-Aminopyridine (4-AP) dramatically enhances transmission at

the neuromuscular junction and other synapses. Consequently the drug has been employed clinically in the treatment of prolonged paralysis caused by antibiotics and muscle relaxants, and in the neuromuscular disorder of Eaton-Lambert syndrome.

We wish to report the results of an acute poisoning misadventure in three adult males. We will review the animal toxicology, summarize the neurophysiological research using 4-AP as a potassium channel blocker, comment on clinical applications, and outline the management of overdose with this agent.

### CASE REPORT

On November 17, 1978, three employees of a Virginia manufacturing plant each consumed a "pinch" of a substance which they thought to be Spanish fly during their morning coffee break at 9:15 AM. The substance was later shown to be reagent grade (99% pure) 4-AP. All three reported a disagreeable taste, immediate burning of the throat, and abdominal discomfort.

Patient A, a 38-year-old, 100 kg male, developed nausea, weakness, dizziness, and intense diaphoresis over the first 15 min. He reported a feeling of impending doom, weakness, dyspnea, and profound thirst. At 10:00 he was seen in his local hospital Emergency Department (ED) with BP 154/60, agitated, and combative. The patient vomited and exhibited "convulsive-like movements." He was treated with diazepam 10 mg IM and 10 mg IV over the next hour and arrived at the University of Virginia Hospital Emergency Department at 11:20 AM.

On arrival he had BP 160/84, P 124, R 36, skin was warm, diaphoretic, and pale. He did not respond to deep pain. He exhibited three generalized tonic-clonic seizures, each lasting about 1 min.

His initial arterial blood pH was 7.40,  $pO_2$  119,  $pCO_2$  13 on mask oxygen with a serum  $HCO_3^-$  of 8 mEq/L. However, following the first seizure his arterial blood gasses were pH 6.87,  $pCO_2$  58,  $pO_2$  230 on 100%  $FIO_2$  and anion gap was 35 mEq/mL. Lactate was 19.9 mEq/L. Other serum electrolytes, glucose, urea nitrogen, creatinine, and other chemistry values were not remarkable. Electrocardiogram showed sinus tachycardia with nonspecific ST-T wave abnormality. Hematocrit was 50%, WBC 24,900 without left shift, and platelets were normal. WBC declined to 13,600 and 10,200 on the next 2 days. He was treated with intubation, ventilation, IV diazepam, nalaxone, diphenhydramine (Benadryl), and sodium bicarbonate. Gastric lavage was performed with a 39 fr (Edlich) tube, and he received activated charcoal (80 gm) and saline cathartic (20 gm  $NaSO_4$ ) via gastric tube.

His arterial pH was 7.47,  $pO_2$  95,  $pCO_2$  24, and  $HCO_3^-$  21 at 14:30 after 300 mEq (8 amp) of sodium bicarbonate. Urine flow was maintained at 150 to 200 mL/hr with IV fluids.

The patient was unarousable at 14:00 (1 hr after the last seizure). Mental status improved rapidly; at 15:45 he complained of abdominal

### POISONING WITH

pain, and at 18:00 entered.

On the following day he complained only of blurred vision. The patient was discharged on the fifth hospital day.

At 1-week post-exposure he had a pruritic rash on his trunk and extremities except for a serous rash on his hands (normal 5 to 10 IU).

Patient B, a 45-year-old male, complained "to dilute the poison" and developed some abdominal pain in the local ED. He was transferred to the University of Virginia Hospital (100, and R 12). He was treated with diazepam and served to be unresponsive.

He arrived at the Emergency Department at 11:00 AM, was confused, and had a pulse of 140. His arterial blood pressure was 160/100. He revealed an anion gap of 35. WBC was 15,000.

The patient's physical examination was normal. He was treated with diazepam and mannitol to reduce intracranial pressure.

Within 2 to 3 days he was discharged and continued to have no clinical or laboratory abnormalities. Included LDH, creatine phosphatase 410 U/L (11/24) except for a mild elevation of SGOT.

Patient B was discharged on the fifth hospital day with no clinical or laboratory abnormalities.

Patient C, a 45-year-old male, was discharged on the fifth hospital day with no clinical or laboratory abnormalities beyond the disagreeable taste.

### Identification

Toxicologic analysis of the substance B using gas-liquid chromatography and spot tests were negative. The substance was identified as a common overdose agent.

pain, and at 18:00 he was alert enough to be extubated but still disoriented.

On the following day (11/18) the patient was alert and oriented and complained only of weakness, light headedness, and difficulty with far vision. The patient continued to improve and was discharged on the fifth hospital day. An EEG performed on the fourth hospital day was interpreted as normal and revealed no seizure focus.

At 1-week postingestion his only complaints were mild anorexia, a pruritic rash on both arms "like poison oak" and back pain (apparently musculoskeletal). His follow-up chemistry screen was unremarkable except for a serum glutamic oxaloacetate transaminase (SGOT) of 55 IU (normal 5 to 40). At 18 days SGOT was 29.

Patient B, a 29-year-old, 100 kg male, reported similar early symptoms. After failing to autoinduce vomiting, he ingested a pint of milk "to dilute the poison." Weakness, nausea, and profuse perspiration developed somewhat more slowly than in Patient A. When he was seen in the local ED at 11:20 his BP was 138/70, P 72, and R 32. At the time of transfer to the University of Virginia Hospital BP was 160/100, P 100, and R 12. His mental status fluctuated and at times he was observed to be unconscious, disoriented, and combative.

He arrived at the University of Virginia Hospital Emergency Department at 11:30 with BP 140/80, P 72, and R 36. He was agitated, confused, and attempted to go home but was prevented by weakness. His arterial blood had pH 7.39, pCO<sub>2</sub> 27, and pO<sub>2</sub> 82. Electrolytes revealed an anion gap of 30 mEq/mL with Na 144, Cl 102, K 2.8, and HCO<sub>3</sub> 15. WBC was 13,600; 5800 on the next 2 days.

The patient was disoriented and shouting incoherently. Physical examination was unremarkable; reflexes were brisk and symmetrical. He was treated with gastric lavage, activated charcoal, Na<sub>2</sub>SO<sub>4</sub>, fluids, and mannitol to maintain urine output of 160 to 230 mL/hr.

Within 2 to 3 hr the patient was oriented to person, place, and time, and continued to improve steadily. Enzymes the second day (11/18) included LDH of 375 (normal 100 to 350), SGOT 51 (4-30), and alkaline phosphatase 41 (20-95). All serum chemistries were normal on Day 8 (11/24) except for SGOT of 26 (2-16).

Patient B was discharged on the fourth hospital day, and exhibited no clinical or biochemical sequelae except for the above-mentioned elevation of SGOT.

Patient C, a 30-year-old male, successfully induced vomiting on himself within 10 min of ingestion and denied any adverse effects beyond the disagreeable taste.

#### Identification

Toxicologic screen of gastric and urine samples of Patients A and B using gas-liquid chromatography, thin-layer chromatography, and spot tests were negative. This effectively ruled out about 90% of the common overdose compounds including phenothiazines, tricyclic anti-

depressants, benzodiazepines, narcotics, barbiturates, and amphetamines. Ethanol and salicylate levels were negligible.

About 10 gm of the light brown, coarse, crystalline substance remained of the "stash." Direct assay by the above methods were unrevealing. Preliminary melting point studies showed that both the purified (by sublimation) and unpurified crystals melted at 158°C compared to 216°C expected for cantharadin (spanish fly). A blister bioassay for cantharadin of 0.5 mg in rabbit ear produced no blister and little difference from ethanol control [11].

Molecular weight of 4-AP by quadrupole mass spectrometry was 94. Chemical ionization with methane gave a molecular weight of 95 and with deuterio methanol gave a molecular weight of 98, suggesting the presence of a single amino group. No substance of this description was listed in the current Merck Index (9th edition). The proton magnetic resonance spectrum of 4-AP exhibited two doublets at 8.1 and 6.6 ppm and a broad signal at 5.45 ppm (Fig. 1). These signals and their integrals match that reported for 4-AP. Both mass spectra and resonance spectra were identical for purified (sublimed) crystals and crude crystals, indicating a high degree of purity. Infrared spectrum was examined for a potassium iodide pellet (Fig. 1) and found to correspond with the published spectrum for 4-AP.

Gas-liquid chromatography methods have been developed for detecting 4-AP in soil and plant tissue [2], but no method to quantitate 4-AP in animal tissue has been reported.

Patients A and B were asked to repeat their "pinch" measurements, and the average pinch weights were 59 and 61 mg, respectively.

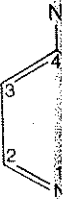
## DISCUSSION

### Toxicology

Avitrol is marketed as poison bait compounded with corn, wheat, sorghum, or peanut butter with 0.03% to 1 4-AP. It is available as a concentrate of 25 or 50% 4-AP cut with powdered sugar. The acute toxicity of 4-AP has been studied in several bird and mammal species [3] (Table 1).

Doses near the LD<sub>50</sub> in mammals produce a usual sequence of symptoms: hyperexcitability, salivation, tremors, muscle incoordination, convulsions, and cardiac or respiratory arrest. Initial symptoms occur within 10 to 15 min with an initial increase in respiratory movements, but progress rapidly to death in 15 min to 4 hr [3]. Two quarter horses ingested about 3 mg/kg, exhibited excitability, profuse sweating, convulsions, and death in 2 hr [4].

The metabolic fate of 4-AP is unclear, but predators ingesting birds killed by 4-AP show no signs of intoxication after 3 to 4 times the LD<sub>50</sub> [5]. No compromise in reproductive performance was detected in quail surviving acute and chronic 4-AP exposure [6] and long-term hazards



RECEIVED




FIG. 1. Proton magnetic resonance spectrum of 4-AP.

to nontarget species. The compound is rapidly absorbed into the bloodstream within 1 to 2 months [8].

### Pharmacology

Pure 4-AP is highly soluble in water. The structure of 4-AP is shown in Figure 1.

tes, and amphetamine. This substance re- methods were unre- that both the puri- at 158°C com- ly). A blister bio- iced no blister and

pectrometry was ular weight of 95 of 98, suggeste of this descrip- tion). The proton o doublets at 8.1 ). These signals Both mass spectra (sublimed) crystals ity. Infrared spec- Fig. 1) and found P.

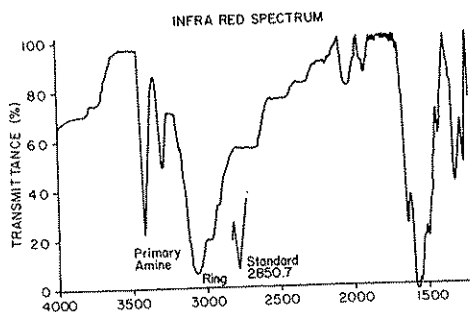
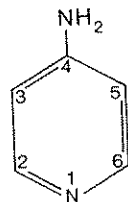
developed for de- thod to quantitate

nch" measurements, respectively.

with corn, wheat, t is available as a ugar. The acute and mammal species

al sequence of muscle incoordina- st. Initial symptoms n respiratory move- hr [3]. Two quarter ty, profuse sweating,

ators ingesting birds 3 to 4 times the LD<sub>50</sub> was detected in quail long-term hazards



PROTON MAGNETIC RESONANCE SPECTRUM

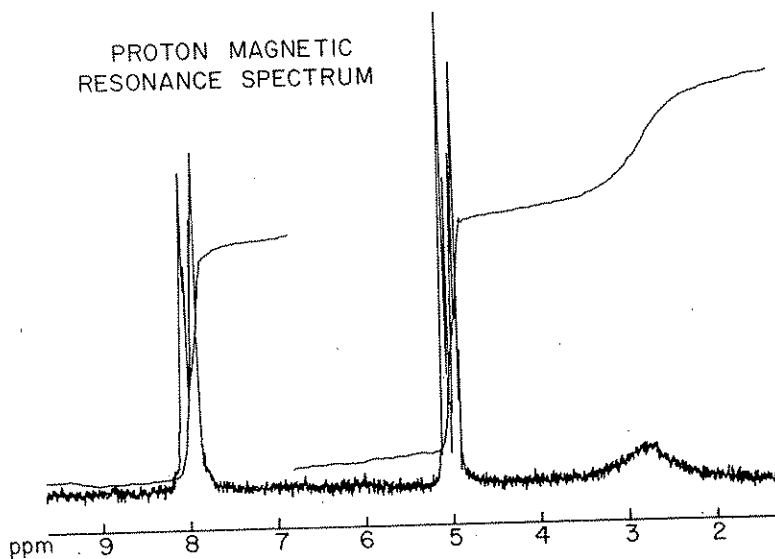


FIG. 1. 4-Aminopyridine; chemical structure, infrared transmittance spectrum, and proton magnetic resonance spectrum.

to nontarget birds and fish appears minimal [7]. 4-AP is strongly adsorbed into the soil, and degradation half-life varies from 3 to 22 months [8].

Pharmacology

Pure 4-AP is an odorless, tan to white crystal, soluble in water 1:8, highly soluble in acetone and EtOH, and melts at 156 to 158°C. The structure is simply a pyridine ring with a single amide in the

TABLE 1. Toxicity of 4-Aminopyridine

Species	LD <sub>50</sub> , mg/kg	
	Oral	Parenteral
Mouse	-	8
Rat	20	7
Chicken	15	-
Dog	4	3.5
Horse	3	-
Cowbird	1	-

4 position (Fig. 1). It is thus a highly polar, nonionic, aromatic compound with a molecular weight of 94.13. The compound has a  $pK_a$  of 9.17 at 20°C, and exists in solution almost totally in the cationic form at physiologic pH. It is rapidly absorbed from the gastrointestinal tract, but apparently poorly absorbed from the skin [9].

There is no pharmacokinetic data yet available, but the volume of distribution of polar compounds frequently approximates extracellular volume fluid, i.e., about 25% of lean body weight. Estimated peak serum concentration would be 2.3  $\mu\text{g}/\text{mL}$  (25 mM) following a 60-mg dose in a 100-kg patient. The metabolism and excretion of this drug are likewise unstudied, but the absence of ill effects to predators eating poisoned birds argues for rapid degradation, probably by acetylation.

In mice, intraperitoneal and intracerebral administrations were equally effective in eliciting seizure activity at doses of 1 mg/kg. In the cats anesthetized with chloralose, 4-AP caused a dramatic increase in systolic blood pressure. Perfused rat hindquarters showed vasoconstriction which occurred after desensitization to epinephrine effects with ergotamine.

### Neuropharmacology

Most of the pharmacologic effects of 4-AP may be attributed to enhanced transmission at the neuromuscular and other synapses. This drug has been shown to reverse neuromuscular blockade caused by d-tubocurarine [10], botulinum toxin [11], and antibiotics [12]. The drug also has a direct effect on muscle fibers to enhance twitch response. Studies in many species have shown that 4-AP blocks the potassium ion current of repolarization following an action potential [13-16]. This blockade of the potassium channel at the level of the

### POISONING WITH

membrane widens neurotransmitter [17]. Concentration produced a decrease is not readily reversed for at least a period.

At much higher action potential. In addition to 4-AP in eliciting seizures are less effective.

### Clinical App

Because of its employed clinical mission. In the associated with action potential administration of pressure or elevated strength (mg/kg). He also to light on dosage parent neoplasms with doses of 0.

In anesthetic curbed as a common antibiotics. Two blockage due to anesthesia received strength as measured about 1 hr, and intensive study, 0.35 mg/kg 4-aminopyridine due to a constant. The authors note confusion, and

Since 4-AP predict the prominent feature of both elevated lactate

membrane widens the action potential and enhances the release of neurotransmitter and thus increases postsynaptic action potentials [17]. Concentrations of 4-AP as low as  $53 \mu\text{M}$  ( $0.5 \mu\text{g/mL}$ ) have produced a decrease in potassium channel current [15]. This decrease is not readily reversible by washing in drug-free medium, arguing for at least a partial intracellular effect [13].

At much higher concentrations (5 mM), 4-AP elevates the cardiac action potential plateau and depresses diastolic depolarization [18]. In addition to 4-AP, the 2- and 3- aminopyridines have similar effects in eliciting seizures and blocking potassium channels; however, they are less effective than 4-AP [13, 19].

### Clinical Applications

Because of its ability to reverse synaptic blockade, 4-AP has been employed clinically in situations of decreased neuromuscular transmission. In the treatment of a patient with Eaton-Lambert syndrome associated with a small cell bronchogenic Ca, the compound muscle action potential returned to normal values with the intravenous administration of 23 mg in divided doses over 2 hr. No change in blood pressure or electrocardiogram was observed. The patient noted improved strength on a dosage of 20 mg of 4-AP five times a day (1.42 mg/kg). He also had increased wakefulness and increased sensitivity to light on dosage of 100 mg/day [20]. In another patient without apparent neoplasm, evoked muscle action potentials improved by 300% with doses of 0.3 and 0.6 mg/kg [21].

In anesthetic practice, prolonged neuromuscular blockade has occurred as a complication of combined use of muscle relaxants and antibiotics. Two patients who developed an enhanced neuromuscular blockade due to lincomycin and pancuronium during the course of anesthesia received intravenous doses of 30 to 35 mg of 4-AP. Muscle strength as measured by twitch activity returned in one case over about 1 hr, and within 10 min in the second case [22]. In a more extensive study, Miller et al. have shown that an intravenous dose of 0.35 mg/kg 4-AP reduced by 65 to 75% the amount of neostigmine or pyridostigmine required to reverse the neuromuscular blockade due to a constant infusion of pancuronium in 57 anesthetized patients. The authors note that doses of 1 mg/kg or more caused restlessness, confusion, and central nervous system excitation postoperatively [23].

### CONCLUSIONS

Since 4-AP can potentially affect every synapse, it is difficult to predict the principal clinical effect. Metabolic acidosis was a prominent feature of both patients studied, with Patient A showing a markedly elevated lactate following his seizures. The increased anion gap in

Patient B may also have been secondary to increased lactate, since increased muscular activity would result from the direct effect of the drug upon the neuromuscular junction and muscle fiber, and indirectly from central nervous system stimulation. The generalized seizure observed in Patient A may also be on the basis of increased synaptic activity. EEG changes have not been demonstrated experimentally. Both poisoned patients exhibited weakness, diaphoresis, altered mental status, and hypertension. The patient who successfully induced vomiting apparently did not absorb significant 4-AP, thus supporting the use of emesis for removal of this poison.

### Management of Overdose

As in all acute poisonings, the principal objectives are support of vital functions and prevention of absorption. Specific steps in management should include:

#### Support vital function:

1. Establish respirations and assure an airway. Tidal volume should be 10 to 15 cc/kg. Cardiopulmonary resuscitation as required.

#### Prevention of absorption:

2. Emesis should be initiated unless the patient is unable to protect his airway (coma, convulsing, no gag reflex). Ipecac dose is 30 mL for adults and 15 mL for children (30 lb), follow with fluids (2 glasses water), ambulate.
3. If emesis is contraindicated, then gastric lavage with a large bore tube should be preceded with endotracheal intubation.
4. Activated charcoal, 10 times the ingested dose or 1 gm/kg, in a water slurry, by mouth or NG tube.
5. Sodium sulfate cathartic, 0.25 gm/kg, in a 10% solution, by mouth or NG tube. May be mixed with the charcoal.

#### Specific measures:

6. Pancuronium is a pharmacologic antagonist and should be considered in the severely poisoned patient. The patient should be intubated and closely monitored.
7. There is evidence that propranolol may block some of the cardiac toxicity of 4-AP, and it should be considered in treatment of serious arrhythmias.
8. Seizures may be treated with IV diazepam, 0.1 mg/kg, max 10 mg per dose, max 60 mg total dose.

Avitrol may be acquired compounded as bird bait. It is also readily available in reagent grade from chemical suppliers. The 10 gm which the patients obtained is about 200 times the lethal dose.

### POISONING W

The doses  
times the dose  
margin is ver  
Paracelsus  
poisons. . . .  
seems partic

Four-amin  
manufacturer  
of birds are  
cry frighteni

Four-amin  
neuromuscul  
clinically in  
and muscle r

In this pap  
ture in three  
ize the neuro  
blocker, com  
of overdose

#### Four-digit m Biometrics

- |     |        |         |
|-----|--------|---------|
| [1] | [4216] | Br. M   |
| [2] | [4948] | pyridin |
|     |        | Toxico  |
| [3] | [4784] | summ    |
|     |        | mamm    |
| [4] | [2979] | tion of |
|     |        | 39, 32  |
| [5] | [4944] | to an   |
|     |        | bait    |
| [6] | [4945] | effec   |
|     |        | reprec  |
|     |        | 13, 75  |

The doses consumed by the patients reported here are only 2 to 3 times the doses employed clinically, and suggest that the therapeutic margin is very small for this agent.

Paracelsus' sixteenth century observation: "All substances are poisons. . . . The right dose differentiates a poison and a remedy" seems particularly apropos to 4-AP.

## SUMMARY

Four-aminopyridine is an acutely toxic avicide considered by the manufacturer to be a bird "repellant" because only a small number of birds are acutely poisoned, become disoriented, and emit a distress cry frightening other members of the flock.

Four-aminopyridine dramatically enhances transmission at the neuromuscular junction and other synapses, and has been employed clinically in the treatment of prolonged paralysis caused by antibiotics and muscle relaxants, and in the Eaton-Lambert syndrome.

In this paper we report the results of an acute poisoning misadventure in three adult males. We review the animal toxicology, summarize the neurophysiological research using 4-AP as a potassium channel blocker, comment on clinical applications, and outline the management of overdose with this agent.

## REFERENCES

Four-digit numbers within brackets refer to University of Virginia Biometrics Master Reference Numbers.

- [1] [4216] L. C. Nickolls and D. Teare, Poisoning by cantharidin, *Br. Med. Jr.*, 1384-1386 (1954).
- [2] [4948] J. E. Peterson, A microanalytical method for 4-aminopyridine in sunflower seeds and plants, *Bull. Environ. Contam. Toxicol.*, 13, 641-645 (1975).
- [3] [4784] E. W. Schafer, R. B. Brunton, and D. J. Cunningham, A summary of the acute toxicity of 4-aminopyridine to birds and mammals, *Toxicol. App. Pharmacol.*, 26, 532-538 (1978).
- [4] [2979] A. C. Ray et al., Clinical signs and chemical confirmation of 4-aminopyridine poisoning in horses, *Am. J. Vet. Res.*, 39, 329-331 (1978).
- [5] [4944] E. W. Schafer, R. B. Brunton, and N. F. Lockyer, Hazards to animals feeding on blackbirds killed with 4-aminopyridine baits, *J. Wildl. Manage.*, 38, 424-426 (1974).
- [6] [4945] E. W. Schafer, R. B. Brunton, and N. F. Lockyer, The effects of subacute and chronic exposure to 4-aminopyridine on reproduction in coturnix quail, *Bull. Environ. Contam. Toxicol.*, 13, 758-764 (1975).

- [7] [4943] E. W. Schafer and L. L. Marking, Long-term effects of 4-aminopyridine exposure to birds and fish, J. Wildl. Manage., 39, 807-811 (1975).
- [8] [4942] R. L. Starr and D. J. Cunningham, Leaching and degradation of 4-aminopyridine 14c in several soil systems, Arch. Environ. Contam. Toxicol., 3, 72-83 (1975).
- [9] [4939] E. W. Schafer, R. B. Brunton, and N. R. Lockyer, Comparative toxicity of 17 pesticides to the quela, house sparrow and red-winged blackbird, Toxicol. Appl. Pharmacol., 26, 154-157 (1973).
- [10] [4894] W. C. Bowman, A. L. Harvey, and I. G. Marshall, The actions of aminopyridines on avian muscle Naunyn Schmiedbergs, Naunyn-Schmiedbergs Arch. Pharmacol., 297, 99-103 (1977).
- [11] [4891] C. Lee, A. J. C. deSilva, and R. L. Katy, Antagonism of polymycin B-induced neuromuscular and cardiovascular depression by 4-aminopyridine in the anesthetized cat, Anesthesiology, 49, 256-259 (1978).
- [12] [4954] L. Burkett et al., Mutual potentiation of the neuromuscular effects of antibiotics and relaxants, Anesth. Analg., 58, 107-115 (1979).
- [13] [4785] J. Z. Yeh, et al., Dynamics of aminopyridine block of potassium channels in squid axon membrane, J. Gen. Psychol., 68, 519-535 (1976).
- [14] [4783] R. Fink and E. Wettwer, Modified k-channel gating by exhaustion and the block by internally applied TEA and 4-aminopyridine in muscle, Pfluegers Arch., 374, 289-292 (1978).
- [15] [4897] W. Ulbricht and H. H. Wagner, Block of potassium channels of the nodal membrane by 4-aminopyridine and its partial removal on depolarization, Pfluegers Arch., 367, 77-87 (1976).
- [16] [4951] N. Pelhate and Y. Pichon, Selective inhibition of potassium current in the giant axon of the cockroach, J. Physiol., 242, 90-91 (1974).
- [17] [4889] R. Llinas, K. Walton, and V. Bohr, Synaptic transmission in squid giant synapses after potassium conductance blockage with external 3- and 4-aminopyridine, Biophys. J., 16, 83-87 (1976).
- [18] [4960] D. J. Snyders and P. P. van Bogaert, Modification of cardiac pacemaker current by 4-aminopyridine, Arch. Int. Physiol. Biochim., 86, 190-191 (1978).
- [19] [4896] F. N. Fastier and M. A. McDowall, A comparison of the pharmacologic properties of the three isomeric aminopyridine, Aust. J. Exp. Biol., 36, 365-372 (1958).
- [20] [4886] H. Lundh, O. Nilsson, and I. Roses, 4-AP: A new drug tested in the treatment of Eaton Lambert syndrome, J. Neurol. Neurosurg. Psychiatry, 40, 1109 (1977).
- [21] [4946] S. Agoston, T. van Weerden, W. Broedert, and A. Broedert, Effects of 4-aminopyridine in Eaton Lambert syndrome, Br. J. Anaesth., 50, 383-385 (1978).

- [22] [4888] mine  
block
- [23] [4855] stigm  
420 (

YKER ET AL.

rm effects of  
Idl. Manage.,

g and degrada-  
is, Arch. En-

ockyer, Com-  
se sparrow and  
26, 154-157

arshall, The  
Schmiedbergs,  
103 (1977).

ntagonism of  
scular depres-  
nesthesiology,

e neuromus-  
Analg., 58,

ne block of  
en. Psychol.,

el gating by  
and 4-amino-  
(1978).

tassium chan-  
d its partial  
77-87 (1976).  
ion of potas-  
Physiol., 242,

c transmission  
ce blockage  
16, 83-87

fication of car-  
. Int. Physiol.

parison of the  
aminopyridine,

A new drug  
e, J. Neurol.

and A. Broe-  
syndrome, Br.

POISONING WITH 4-AMINOPYRIDINE

497

- [22] [4888] L. H. D. J. Booij, R. D. Miller, and J. F. Crul, Neostigmine and 4-aminopyridine antagonism of lincomycin-pancuronium blockade in man, Anesth. Analg., 57, 316-321 (1978).
- [23] [4855] R. D. Miller et al., 4-Aminopyridine potentiates neostigmine and pyridostigmine in man, Anesthesiology, 50, 416-420 (1976).